CLINICAL ORAL IMPLANTS RESEARCH

*Mario Bassetti**
*Dorothee Schär**
Beat Wicki
Sigrun Eick
Christoph A. Ramseier
Nicole B. Arweiler
Anton Sculean
Giovanni E. Salvi

Anti-infective therapy of peri-implantitis with adjunctive local drug delivery or photodynamic therapy: 12-month outcomes of a randomized controlled clinical trial

Authors' affiliations:
Mario Bassetti, Dorothee Schär, Beat Wicki, Sigrun Eick, Christoph A. Ramseier, Anton Sculean, Giovanni E. Salvi, Department of Periodontology, School of Dental Medicine, University of Bern, Bern, Switzerland
Nicole B. Arweiler, Department of Periodontology, Philipps University, Marburg, Germany

Corresponding author:
Prof. Dr Giovanni E. Salvi
University of Bern
School of Dental Medicine
Departement of Periodontology
Freiburgstrasse 7
CH-3010 Bern, Switzerland
Tel.: +41 31 632 25 89
Fax: +41 31 632 49 15
e-mail: giovanni.salvi@zmk.unibe.ch

Key words: clinical research, clinical trials, drug delivery, laser, microbiology, pharmacology, wound healing

Abstract

Objective: The objective of the study is to compare the clinical, microbiological and host-derived effects in the non-surgical treatment of initial peri-implantitis with either adjunctive local drug delivery (LDD) or adjunctive photodynamic therapy (PDT) after 12 months.

Materials and Methods: Forty subjects with initial peri-implantitis, that is, pocket probing depths (PPD) 4–6 mm with bleeding on probing (BoP) and radiographic bone loss $\leq$2 mm, were randomly assigned to two treatment groups. All implants were mechanically debrided with titanium curettes and with a glycine-based powder airpolishing system. Implants in the test group (N = 20) received adjunctive PDT, whereas minocycline microspheres were locally delivered into the peri-implant pockets of control implants (N = 20). At sites with residual BoP, treatment was repeated after 3, 6, 9 and 12 months. The primary outcome variable was the change in the number of peri-implant sites with BoP. Secondary outcome variables included changes in PPD, clinical attachment level (CAL), mucosal recession (REC) and in bacterial counts and crevicular fluid (CF) levels of host-derived biomarkers.

Results: After 12 months, the number of BoP-positive sites decreased statistically significantly ($P < 0.05$) from baseline in both groups (PDT: 4.03 $\pm$ 1.66–1.74 $\pm$ 1.37, LDD: 4.41 $\pm$ 1.47–1.55 $\pm$ 1.26). A statistically significant ($P < 0.05$) decrease in PPD from baseline was observed at PDT-treated sites up to 9 months (4.19 $\pm$ 0.55 mm to 3.89 $\pm$ 0.68 mm) and up to 12 months at LDD-treated sites (4.39 $\pm$ 0.77 mm to 3.83 $\pm$ 0.85 mm). Counts of *Porphyromonas gingivalis* and *Tannerella forsythia* decreased statistically significantly ($P < 0.05$) from baseline to 6 months in the PDT and to 12 months in the LDD group, respectively. CF levels of IL-1β decreased statistically significantly ($P < 0.05$) from baseline to 12 months in both groups. No statistically significant differences ($P > 0.05$) were observed between groups after 12 months with respect to clinical, microbiological and host-derived parameters.

Conclusions: Non-surgical mechanical debridement with adjunctive PDT was equally effective in the reduction of mucosal inflammation as with adjunctive delivery of minocycline microspheres up to 12 months. Adjunctive PDT may represent an alternative approach to LDD in the non-surgical treatment of initial peri-implantitis.

*Both authors contributed equally to the manuscript.

Date:
Accepted 13 February 2013

To cite this article:
Bassetti M, Schär D, Wicki B, Eick S, Ramseier CA, Arweiler NB, Sculean A, Salvi GE. Anti-infective therapy of peri-implantitis with adjunctive local drug delivery or photodynamic therapy: 12-month outcomes of a randomized controlled clinical trial.
Clin. Oral Impl. Res. **25**, 2014, 279–287
doi: 10.1111/clr.12155

Outcomes from long-term studies with a mean follow-up of at least 10 years indicated that the use of titanium dental implants represents a predictable treatment approach for the prosthetic rehabilitation of fully (Ueda et al. 2011; Frisch et al. 2012) and partially (Buser et al. 2012; Dierens et al. 2012) edentulous patients. Peri-implant inflammatory processes (e.g. bleeding and/or suppuration) associated with radiographic bone loss (i.e. peri-implantitis), however, have been shown to occur more frequently in periodontally susceptible patients (Hardt et al. 2002; Karoussis et al. 2003; De Boever et al. 2009; Matarasso et al. 2010; Roccuzzo et al. 2010, 2012) and tobacco smokers

© 2013 John Wiley & Sons A/S. Published by Blackwell Publishing Ltd

(Aglietta et al. 2011) compared with periodontally healthy and non-smoking patients. The presence of biofilms dominated by Gram-negative anaerobic bacteria has been associated with sites characterized by peri-implantitis (Salcetti et al. 1997; Leonhardt et al. 1999; Hultin et al. 2002). Hence, from a therapeutic point of view, implant surface decontamination and resolution of inflammation represent the main objectives in the treatment of peri-implantitis. Impaired access for plaque control around the prosthetic reconstruction (Serino & Ström 2009) and surface roughness of the contaminated implant (Subramani et al. 2009), however, limit the reduction of the bacterial load at sites with peri-implantitis and resolution of inflammation is often incomplete. A modest reduction in mucosal inflammation was observed when implants affected by peri-implantitis were treated only by means of carbon fibre curettes or with the Vector® system, respectively (Karring et al. 2005). Pocket probing depths, however, remained unaffected (Karring et al. 2005). These results were duplicated when mechanical debridement alone of peri-implantitis was performed either with titanium curettes or with the Vector® system (Renvert et al. 2009). Although plaque and bleeding scores improved, no significant reductions in pocket probing depths were observed (Renvert et al. 2009). Therefore, in the non-surgical management of peri-implantitis, the effects of adjunctive therapies to mechanical debridement alone such as the delivery of antiseptics and antibiotics and the use of lasers and air-polishing devices were investigated. Mechanical debridement of peri-implantitis lesions in conjunction with the placement of non-resorbable tetracycline fibres yielded clinical benefits in terms of reductions in pocket probing depth and bleeding tendency after 12 months (Mombelli et al. 2001). Clinical and microbiological improvements of peri-implantitis lesions were also reported after adjunctive delivery of local resorbable antibiotics and chlorhexidine gel (Büchter et al. 2004; Renvert et al. 2004, 2006, 2008; Persson et al. 2006; Salvi et al. 2007). Complete resolution of mucosal inflammation, however, remained unpredictable after adjunctive delivery of antiseptics and antibiotics to the mechanical debridement of peri-implantitis lesions. The application of photodynamic therapy (PDT) was investigated as a further approach in the bacterial decontamination of implants affected by peri-implantitis. After treatment of experimentally induced peri-implantitis in dogs with toluidine blue O (TBO)-mediated PDT, a reduction in the counts of *Prevotella intermedia/nigrescens*, *Fusobacterium* spp., and *beta-haemolytic* streptococci was reported (Shibli et al. 2003). No differences with respect to reduction in counts of *Prevotella* sp., *Fusobacterium* spp., and *beta-haemolytic* streptococci, however, were observed comparing the treatment of peri-implantitis with azulene-mediated PDT with that of a muco-periosteal flap and adjunctive irrigation of chlorhexidine (Hayek et al. 2005). *In vitro* outcomes showed that PDT mediated by methylene blue dye and chlorhexidine were more efficient than laser irradiation alone in the bacterial decontamination of anodized rough titanium surfaces (Marotti et al. 2012). Results of a histomorphometric study indicated that bacterial decontamination with toluidine blue O-mediated PDT of smooth and rough titanium discs implanted subcutaneously in rats was superior compared with other methods of decontamination over a period of 7 days (Salmeron et al. 2012).

Recent outcomes of a randomized clinical trial showed that adjunctive delivery of minocycline microspheres or PDT to the non-surgical mechanical debridement of initial peri-implantitis lesions yielded comparable clinical outcomes after 6 months with respect to the reduction of bleeding sites and pocket probing depths as well as attachment level gain (Schär et al. 2013).

Hence, based on these 6-month outcomes (Schär et al. 2013), the aims of the present randomized controlled clinical trial were (i) to assess whether the 6-month outcomes could be sustained up to 12 months and (ii) whether the changes in clinical parameters could be explained by changes in microbiological and host-derived parameters.

Material and methods

Study design

This study was designed and performed as a prospective randomized clinical trial of 12 months duration. The study protocol was submitted to and approved by the Ethical Committee of the Canton Bern, Switzerland (KEK approval Nr. 79/10).

Subject selection

After completion of periodontal and implant therapy, all subjects had been enroled in a regular supportive periodontal therapy (SPT) programme either at the Department of Periodontology of the University of Bern, Switzerland, or in private practice. The individually tailored recall appointments were scheduled independently of the 3-month treatment intervals. Study implants were excluded from SPT provided at the recall appointments.

Subjects were included based on the following criteria:

(1) Age $\geq$ 18 years.
(2) Absence of relevant medical conditions.
(3) Partially edentulous subjects with healthy or treated periodontal conditions enroled in a regular supportive care programme.
(4) Initial peri-implantitis defined as:
   a pocket probing depth (PPD) of 4–6 mm with concomitant bleeding on probing (BoP) at $\geq$ 1 peri-implant site and.
   b radiographic marginal bone loss ranging from 0.5 to 2 mm between delivery of the suprastructure and pre-screening appointment.
(5) Implant in function for $\geq$ 1 year.
(6) Solid-screw tissue level titanium implants with a sandblasted and acid-etched (SLA) surface (Straumann® Dental Implant System, Institut Straumann AG, Basel, Switzerland).
(7) Full-Mouth Plaque Score (FMPS) $\leq$ 25.
(8) Full-Mouth Bleeding Score (FMBS) $\leq$ 25.

Subjects were excluded based on the following criteria:

(1) Uncontrolled medical conditions.
(2) Pregnant or lactating females.
(3) Tobacco smoking.
(4) Untreated periodontal conditions.
(5) Use of antibiotics in the past 3 months.
(6) Subjects treated for $\geq$ 2 weeks with any medication known to affect soft tissue conditions (e.g. phenytoin, calcium antagonists, cyclosporin, coumadin and non-steroidal anti-inflammatory drugs) within 1 month of the baseline examination.
(7) Peri-implant mucositis defined as the absence of radiographic marginal bone loss between delivery of the suprastructure and pre-screening appointment.
(8) Failure to sign written informed consent.

Null hypothesis

No statistically significant differences are observed with respect to the clinical (e.g. BoP, PPD, REC, CAL), microbiological and host-derived parameters between the two treatment modalities (i.e. adjunctive PDT vs. adjunctive LDD).

Primary and secondary outcome variables

The primary outcome variable was the change in the number of peri-implant sites with bleeding on probing (BoP^+). Secondary

© 2013 John Wiley & Sons A/S. Published by Blackwell Publishing Ltd

outcome variables included the changes in the clinical parameters PPD, REC and CAL as well as changes in microbiological and host-derived parameters in the crevicular fluid (CF).

Sample size calculation

A sample size of 20 subjects per group resulted in a power of 63% to detect a mean difference of one BoP^+ site out of six sites per implant with a standard deviation of 1.3 (Fisher's exact test). The calculated means and standard deviations were based on the 3-month outcomes by Schwarz et al. (2005).

Assessment of clinical parameters

One blinded and calibrated examiner (C. A. R.) assessed the clinical parameters at six sites per implant (e.g. disto-buccal, buccal, mesio-buccal, disto-oral, oral, mesio-oral) with a colour-coded periodontal probe (UNC15, Hu-Friedy, Chicago, IL, USA). The applied probing force ranged from 0.15 to 0.25 N. The implant shoulder was used as landmark for the calculation of the mucosal recession and clinical attachment level.

The following clinical parameters were assessed at baseline, 3, 6, 9 and 12 months:

(1) Pocket Probing Depth (PPD).
(2) Clinical Attachment Level (CAL).
(3) Mucosal recession (REC).
(4) Bleeding on Probing (BoP) (Lang et al. 1986).
(5) Modified Plaque Index (mPlI) (Mombelli et al. 1987).

Treatment of peri-implantitis

Only subjects with one implant fulfilling the definition of initial peri-implantitis were included in the study. If additional implants in the same subject were affected by more advanced peri-implantitis, treatment was provided according to the same protocol but the implants were not included in the evaluation.

All treatment procedures were provided by two operators (D. S. and M. B.). At baseline, all subjects received instructions in the use of superfloss (Superfloss Oral-B, Procter & Gamble, Cinncinati, Ohio and Emoform Duofloss, Natim Handels GmbH, St. Stefan, Austria) around the neck of the implant. The peri-implant soft tissues were anesthetized with articain (Ubistesin™, 3M ESPE AG, Seefeld, Germany) before mechanical debridement was provided. Mechanical debridement was carried out with titanium currettes (Deppeler SA, Rolle, Switzerland) and a glycine-based powder airpolishing for submucosal biofilm removal (Air-Flow Master®, Perio Powder®, Perio-Flow® nozzle, E.M.S. Electro Medical Systems SA, Nyon, Switzerland).

Implants in the test group received adjunctive photodynamic therapy (PDT). This was performed with a set-up for PDT (HELBO® Photodynamic Systems GmbH, Wels, Austria), including a hand-held diode laser (HELBO® TheraLite Laser, HELBO® 3D Pocket Probe, Photodynamic Systems GmbH) with a wavelength of 660 nm and a power density of 100 mW. The dye phenothiazine chloride (HELBO® Blue Photosensitizer, Photodynamic Systems GmbH) was applied submucosally from the bottom to the top of the peri-implant pockets and was left *in situ* for 3 min. Subsequently, the pockets were irrigated with 3% hydrogen peroxide according to the manufacturer's instructions. Each pocket was exposed to the laser light for 10 s. Adjunctive PDT was repeated 1 week later according to the manufacturer's instructions. Subjects were instructed to continue flossing the day after treatment.

Implants in the control group received adjunctive delivery of one unit-dosage of minocycline hydrochloride microspheres (OraPharma Inc., Horsham, PA, USA). Each unit-dosage cartridge delivers minocycline hydrochloride microspheres equivalent to 1 mg of minocycline. As with the implants in the test group, prior to Arestin® application, the pocket was irrigated with 3% hydrogen peroxide. Subjects in the control group were instructed to discontinue submucosal flossing for 10 days to avoid mechanical removal of the minocycline microspheres.

Check-ups and reinforcement of oral hygiene instructions followed at weeks 1, 2, 4 and 8. Clinical follow-up assessments were performed after 3, 6, 9 and 12 months from baseline. In both groups, repeated treatments equivalent to initial therapy were provided at each implant site displaying bleeding on probing after 3, 6, 9 and 12 months.

Collection of CF and microbiological samples

The collection of CF samples was performed first followed by the microbiological sampling. Crevicular fluid and microbiological samples were collected from the implant sites displaying the deepest PPD at baseline. These predetermined sites remained the same throughout the study period. The CF and microbiological samplings were carried out at baseline and after 3, 6 and 12 months.

Host-derived biomarkers sampling and analysis

The sites were isolated with cotton rolls and a saliva ejector and gently air-dried after removal of the supramucosal biofilm. The CF samples were collected by means of sterile paper strips (Periopaper, Oraflow Inc, Smithtown, NY, USA) placed at the entrance of the crevice and left in place for 30 s. Subsequently, the paper strips were placed into a screw top plastic vial and placed immediately into dry ice. Paper strips were stored at −80°C until assayed. One day before analysis, samples were eluted at 4°C overnight into 750 µl phosphate buffered saline (PBS) containing proteinase inhibitors (Sigma-Aldrich, St. Louis, MO, USA). The levels of total interleukin-1beta (IL-1β), interleukin-8 (IL-8), interleukin-10 (IL-10), matrix-metalloproteinase-1 (MMP-1) and matrix-metalloproteinase-8 (MMP-8) in the CF were determined according to the manufacturer's instructions using commercially available enzyme-linked immunosorbent assay (ELISA) kits (R&D Systems Europe Ltd, Abingdon, UK). The detection levels of the kits were 2.5 pg/site for IL-1β, IL-8, IL-10, MMP-1 and 25 pg/site for MMP-8.

Submucosal bacterial sampling and analysis

The implant was isolated with cotton rolls and submucosal plaque samples were collected for 15 s with sterile absorbent paper points (ISO 055, Dentsply Maillefer, Montigny Le Bretonneux, France).

DNA was extracted using Chelex Method (Yang et al. 2008). Real-time PCR for *Porphyromonas gingivalis, Tannerella forsythia*, *Treponema denticola*, *Aggregatibacter actinomycetemcomitans*, *Prevotella intermedia*, *Campylobacter rectus*, *Fusobacterium nucleatum*, *Capnocytophaga gingivalis*, *Parvimonas micra, Eubacterium nodatum* and *Eikenella corrodens* was carried out as described by Eick et al. (2011) using GoTaq® qPCR Master Mix (Promega Corporation, Madison, WI, USA).

Data analysis

Only one implant per subject was included in the study. Therefore, each variable was analysed on a subject level.

Descriptive statistics present an overview of the study sample. Mean values and standard deviations (SD) were calculated for every variable and for every assessment timepoint. Mean values ± SD of the parameters assessed around implants in the test group (PDT) and in the control group (LDD) were compared with the unpaired Student's t-test. Levels of significance within each group between baseline and the 3-, 6-, 9- and 12-month assessments were calculated with the paired Student's t-test and the Wilcoxon's signed rank test. Adjustments were made for multiple comparisons.

The difference in proportion of subjects with a history of treated periodontitis was tested using the chi-square test. The

© 2013 John Wiley & Sons A/S. Published by Blackwell Publishing Ltd

Mann–Whitney *U*-test was used to assess the differences in the mean number of implants and in the mean number of implants with peri-implantitis between subjects in the test and control group.

Parameter-free tests were used for the statistical analysis of the microbiological and host-derived biomarkers data. The Wilcoxon's signed rank test was used to compare the 3-, 6-, 9- and 12-month data with baseline data. Adjustments were made for multiple comparisons. The Mann–Whitney *U*-test was used to analyse differences between the two groups.

The Spearman rank correlation coefficient was used to report correlations between clinical and microbiological and host-derived parameters.

The level of significance was set at $\alpha = 0.05$.

Results

Forty subjects with at least one implant each with initial peri-implantitis were recruited for the study. Each group consisted of 20 subjects. One subject in the PDT group did not attend the 9-month follow-up and another subject in the same group did not attend the 12-month follow-up. No adverse events related to both treatments were reported.

A statistically significantly higher ($P = 0.002$) proportion of subjects (90%) who received adjunctive PDT had a history of treated periodontitis compared with that (40%) in the group who received adjunctive LDD. In addition, subjects in the PDT-treated group had a statistically significantly higher mean number of implants (3.5 vs. 1.9, $P = 0.003$) and a statistically significantly higher mean number of implants with peri-implantitis (2.1 vs. 1.2, $P = 0.009$) compared with those in the LDD-treated group.

After study completion, three subjects in the LDD group and two subjects in the PDT group underwent additional surgical therapy at the experimental implants.

Baseline demographic characteristics of the subject sample are summarized in Table 1.

Table 1. **Demographic characteristics of the study sample at baseline (from Schär et al. 2013)**

	All	Local drug delivery (LDD) (Control group)	Photodynamic therapy (PDT) (Test group)
Number of subjects	40	20	20
Gender (males/females)	20/20	10/10	10/10
Mean age (years) (range)	58 (27–78)	57 (29–75)	59 (27–78)
Mean time (years) after implant placement (range)	7.4 (2.6–15)	7.2 (2.6–15)	7.3 (4–14.8)
Subjects with a history of treated periodontitis	26	8	18
Number of implants placed	107	37	70
Mean number of implants per subject	2.7	1.9	3.5
Number of implants with peri-implantitis	67	24	43
Mean number of implants/subject with peri-implantitis	1.8	1.2	2.1

Table 2. **Mean number of BoP-positive sites ± SD at baseline and after 3, 6, 9 and 12 months**

	Baseline	3 months	6 months	9 months	12 months
LDD group ($N = 20$)	4.41 ± 1.47	2.20 ± 1.28*	2.10 ± 1.55†	1.55 ± 1.79‡	1.55 ± 1.26§
PDT group ($N = 20$)	4.03 ± 1.66	2.26 ± 1.28*	1.51 ± 1.41†	1.48 ± 1.26 ($N = 19$)‡	1.74 ± 1.37 ($N = 19$)§

LDD, local drug delivery; PDT, photodynamic therapy; SD, standard deviation.
*Statistically significant change from baseline to 3 months.
†Statistically significant change from baseline to 6 months.
‡Statistically significant change from baseline to 9 months.
§Statistically significant change from baseline to 12 months.

Bleeding on probing

Table 2 summarizes the mean values ± SD of BoP-positive sites from baseline to 3, 6, 9 and 12 months. At baseline, the mean number of BoP-positive sites per implant amounted to 4.03 ± 1.66 in the test group and to 4.41 ± 1.47 in the control group. No statistically significant difference ($P > 0.05$) was detected at baseline between the two groups. Nine months after therapy, the reduction in sites with BoP amounted to 65% in the LDD and 63% in the PDT group and after 12 months to 65% in the LDD and to 57% in the PDT group, respectively. No statistically significant difference ($P > 0.05$) was observed between groups after 9 and 12 months.

A complete resolution of mucosal inflammation after 9 months was detected in 35% of the patients in the LDD group and in 42.1% of the patients in the PDT group. After 12 months, the corresponding percentages remained unchanged in the LDD group and amounted to 31.6% in the PDT group.

In the LDD group, of the 44 sites BoP^+ at 3 months, 21 sites were still BoP^+ after 6 months, 15 BoP^+ after 9 months and 13 BoP^+ after 12 months. In the PDT group, 45 sites showed BoP^+ after 3 months. Of these 45 sites, 16 sites were still BoP^+ after 6 months, 14 BoP^+ after 9 months and 17 BoP^+ after 12 months.

Among the 40 subjects, a statistically significant correlation between BoP scores and MMP-1 levels after 6 ($r = 0.430$; $P = 0.006$) and 12 months ($r = 0.479$; $P = 0.002$) was observed. Moreover, the BoP scores were statistically significantly correlated with MMP-8 levels ($r = 0.504$; $P = 0.001$) and with IL-8 levels ($r = 0.554$; $P < 0.001$) after 12 months.

Pocket probing depth

Mean values ± SD of PPD at baseline and after 3, 6, 9, and 12 months are presented in Table 3. At baseline, the mean PPD value amounted to 4.39 ± 0.77 mm at implants in the LDD and to 4.19 ± 0.55 mm at implants in the PDT group, respectively. Between baseline and the 9-month follow-up, the reduction in PPD was statistically significant ($P < 0.04$) in both groups (LDD group: 0.45 mm, PDT group: 0.30 mm). After 12 months, PPD reduction from baseline was statistically significant ($P < 0.001$) only in the LDD-treated group (0.56 mm) but not ($P > 0.2$) in the PDT-treated group (0.11 mm). The between-group comparison revealed no statistically significant difference ($P > 0.05$) at baseline, 9 and 12 months.

Table 3. **Mean pocket probing depth (mm) ± SD at each implant at baseline and after 3, 6, 9 and 12 months**

	Baseline	3 months	6 months	9 months	12 months
LDD group ($N = 20$)	4.39 ± 0.77	3.93 ± 0.59*	3.90 ± 0.78†	3.94 ± 0.77‡	3.83 ± 0.85§
PDT group ($N = 20$)	4.19 ± 0.55	3.92 ± 0.61*	3.83 ± 0.58†	3.89 ± 0.68 ($N = 19$)‡	4.08 ± 0.81 ($N = 19$)

LDD, local drug delivery; PDT, photodynamic therapy; SD, standard deviation.
*Statistically significant change from baseline to 3 months.
†Statistically significant change from baseline to 6 months.
‡Statistically significant change from baseline to 9 months.
§Statistically significant change from baseline to 12 months.

© 2013 John Wiley & Sons A/S. Published by Blackwell Publishing Ltd

Clinical attachment level

Table 4 presents the mean CAL ± SD values at baseline and after 3, 6, 9 and 12 months. At baseline, the mean CAL amounted to 2.72 ± 0.72 mm in the LDD group and to 2.66 ± 0.73 mm in the PDT group. No statistically significant changes ($P > 0.05$) were observed over time and between both groups.

Mucosal recession

At baseline, the location of the restoration margins in the LDD group was submucosal in 96 sites, at the mucosal margin in 13 sites and supramucosal in 11 sites. The corresponding values in the PDT group were 99 sites with submucosal restoration margins, 12 sites at the mucosal margin and nine sites with supramucosal margins.

Table 5 shows the mean values ± SD of mucosal recessions at baseline and after 3, 6, 9 and 12 months. The mean baseline values were 1.68 ± 1.04 mm in the LDD and 1.53 ± 0.91 mm in the PDT group, respectively. A statistically significant change ($P < 0.04$) from baseline was observed only after 9 months in the LDD group. No statistically significant changes ($P > 0.05$) were observed in both groups between baseline and the 12-month follow-up. Furthermore, no statistically significant differences ($P > 0.05$) between groups were found at the after 9- and 12-month appointments, respectively.

Modified Plaque Index

Mean values ± SD of the mPlI at baseline and after 3, 6, 9 and 12 months are presented in Table 6. Statistically significant changes were observed over the 12-month study period in both groups. However, no statistically significant differences ($P > 0.5$) were found between groups at baseline and at completion of the study.

Microbiological outcomes

Table 7 presents the bacterial counts in both groups at baseline and after 3, 6 and 12 months categorized into samples being positive and with $\geq 10^5$ bacteria per site. With the exception of *C. rectus* at baseline ($P < 0.01$), the counts in the submucosal biofilm was not statistically significant different between the two groups at any time point. At baseline, the most frequently identified species in the submucosal biofilm were *C. gingivalis*, *F. nucleatum*, *P. micra* and *T. forsythia*.

Three months after baseline, statistically significantly lower counts of three bacterial species in the PDT group (*P. gingivalis*, *T. forsythia* and *T. denticola*) and of seven bacterial species in the LDD group (*P. gingivalis*, *T. forsythia*, *T. denticola*, *P. intermedia*, *C. rectus*, *F. nucleatum* and *E. corrodens*) were observed. The bacterial load of the red complex (Socransky et al. 1998) was statistically significantly reduced ($P < 0.05$) in both groups.

Six months after baseline, a statistically significant decrease in the counts of *P. gingivalis* ($P < 0.05$), *T. forsythia* ($P < 0.01$) and *F. nucleatum* ($P < 0.05$) was observed in the PDT group. In the LDD group, the counts *P. gingivalis* ($P < 0.05$), *T. forsythia* ($P < 0.01$), *T. denticola* ($P < 0.01$), *C. rectus* ($P < 0.01$), *F. nucleatum* ($P < 0.01$), *E. nodatum* ($P < 0.05$) and *E. corrodens* ($P < 0.01$) decreased statistically significantly.

Twelve months after baseline, no statistically significant difference with the exception of *F. nucleatum* ($P < 0.05$) was found with respect to bacterial counts in the PDT group. In the LDD group, the counts of *P. gingivalis* ($P < 0.05$), *T. forsythia* ($P < 0.01$), *T. denticola* ($P < 0.05$), *C. rectus* ($P < 0.01$), *F. nucleatum* ($P < 0.01$) and *E. corrodens* ($P < 0.01$) demonstrated a statistically significant decrease from baseline.

No statistically significant correlations were found between BoP scores and submucosal bacterial species.

Levels of host-derived biomarkers in the crevicular fluid

The median levels and the 25 and 75 percentiles of MMP-8 in the CF are presented in Fig. 1. With the exception of a statistically significant decrease ($P < 0.05$) in median CF levels after 3 months in the LDD group, no statistically significant changes from baseline in MMP-8 levels in the CF were observed.

The median levels and the 25 and 75 percentiles of MMP-1 in the CF are presented in Fig. 2. No statistically significant changes from baseline were detected at any time point in both groups.

Figure 3 presents the median levels and the 25 and 75 percentiles of IL-1β in the CF. The mean CF levels of IL-1β in the LDD group showed a statistically significant decrease from baseline to 3 months ($P < 0.05$), 6 months ($P < 0.01$) and 12 months ($P < 0.05$), respectively. In the PDT group, only the mean CF levels of IL-1β at 12 months differed statistically significantly ($P < 0.05$) from those at baseline.

Figure 4 presents the median levels and the 25 and 75 percentiles of IL-8 in the CF. With the exception of a statistically significant decrease ($P < 0.01$) of mean CF levels of IL-8 after 3 and 6 months in the LDD group, no statistically significant differences in mean levels of IL-8 in the CF were detected in both groups over time.

Figure 5 presents the median levels and the 25 and 75 percentiles of IL-10 in the CF. Compared with baseline, the median CF levels of

Table 4. **Mean clinical attachment level (mm) ± SD at baseline and after 3, 6, 9 and 12 months**

	Baseline	3 months	6 months	9 months	12 months
LDD group ($N = 20$)	2.72 ± 0.72	2.62 ± 0.68	2.53 ± 0.65	2.54 ± 0.63	2.41 ± 0.70
PDT group ($N = 20$)	2.66 ± 0.73	2.66 ± 0.83	2.50 ± 0.77	2.54 ± 0.75 ($N = 19$)	2.58 ± 0.94 ($N = 19$)

LDD, local drug delivery; PDT, photodynamic therapy; SD, standard deviation.

Table 5. **Mean mucosal recession (mm) ± SD at baseline and after 3, 6, 9 and 12 months**

	Baseline	3 months	6 months	9 months	12 months
LDD group ($N = 20$)	1.68 ± 1.04	1.30 ± 0.10*	1.38 ± 1.02†	1.4 ± 1.06	1.41 ± 1.18
PDT group ($N = 20$)	1.53 ± 0.91	1.26 ± 0.88*	1.33 ± 0.90†	1.34 ± 0.94 ($N = 19$)‡	1.5 ± 0.86 ($N = 19$)

LDD, local drug delivery; PDT, photodynamic therapy; SD, standard deviation.
*Statistically significant change from baseline to 3 months.
†Statistically significant change from baseline to 6 months.
‡Statistically significant change from baseline to 9 months.

Table 6. **Mean mPII ± SD at treated implants at baseline and after 3, 6, 9 and 12 months**

	Baseline	3 months	6 months	9 months	12 months
LDD group ($N = 20$)	0.21 ± 0.27	0.01 ± 0.04*	0.03 ± 0.15†	0.04 ± 0.15‡	0.00 ± 0.00§
PDT group ($N = 20$)	0.13 ± 0.21	0.01 ± 0.04*	0.00 ± 0.00†	0.00 ± 0.00 ($N = 19$)‡	0.01 ± 0.04 ($N = 19$)§

LDD, local drug delivery; PDT, photodynamic therapy; SD, standard deviation.
*Statistically significant change from baseline to 3 months.
†Statistically significant change from baseline to 6 months.
‡Statistically significant change from baseline to 9 months.
§Statistically significant change from baseline to 12 months.

© 2013 John Wiley & Sons A/S. Published by Blackwell Publishing Ltd

Table 7. **Bacterial counts at baseline and after 3, 6 and 12 months after therapy**

	BaselinePositive (%)/ $\geq 10^5$ (%)	3 months Positive (%)/ $\geq 10^5$ (%)	6 months Positive (%)/ $\geq 10^5$ (%)	12 months Positive (%)/ $\geq 10^5$ (%)
Porphyromonas gingivalis				
PDT	5 (25)/2 (10)	5 (25)/0 (0)*	6 (30)/0 (0)*	4 (21)/0 (0)
LDD	10 (50)/5 (25)	9 (45)/1 (5)*	4 (20)/1 (5)*	4 (20)/1 (5)*
Tannerella forsythia				
PDT	11 (55)/4 (20)	4 (20)/0 (0)**	6 (30)/1 (5)**	7 (37)/2 (11)
LDD	13 (65)/6 (30)	5 (25)/1 (5)**	6 (30)/1 (5)**	8 (40)/2 (10)**
T. denticola				
PDT	8 (40)/2 (10)	3 (15)/0 (0)*	4 (20)/0 (0)	3 (16)/1 (5)
LDD	10 (50)/3 (15)	3 (15)/0 (0)**	4 (20)/1 (5)**	4 (20)/1 (5)*
Aggregatibacter actinomycetemcomitans				
PDT	7 (35)/1 (5)	6 (30)/0 (0)	3 (15)/0 (0)	6 (32)/0 (0)
LDD	7 (35)/2 (10)	8 (40)/0 (0)	5 (25)/0 (0)	7 (35)/0 (0)
Prevotella intermedia				
PDT	6 (30)/2 (10)	5 (25)/1 (5)	5 (25)/0 (0)	6 (32)/2 (11)
LDD	6 (30)/0 (0)	3 (15)/0 (0)*	4 (20)/0 (0)	4 (20)/0 (0)
Campylobacter rectus				
PDT	6 (30)/3 (15)	4 (20)/1 (5)	3 (15)/1 (5)	8 (42)/2 (11)
LDD	17 (85)/3 (15)‡‡	5 (25)/1 (5)**	7 (35)/0 (0)**	7 (35)/0 (0)**
Fusobacterium nucleatum				
PDT	19 (95)/9 (45)	12 (60)/3 (15)	16 (80)/3 (15)*	14 (74)/2 (11)*
LDD	19 (95)/12 (60)	14 (70)/3 (15)**	17 (85)/3 (15)**	15 (75)/3 (15)**
Capnocytophaga gingivalis				
PDT	20 (100)/1 (5)	20 (100)/1 (5)	20 (100)/2 (10)	19 (100)/2 (11)
LDD	20 (100)/5 (25)	20 (100)/1 (5)	20 (100)/1 (5)	20 (100)/2 (10)
Parvimonas micra				
PDT	13 (65)/3 (15)	13 (65)/1 (5)	11 (55)/1 (5)	14 (74)/0 (0)
LDD	14 (70)/5 (25)	11 (55)/3 (15)	11 (55)/2 (10)	16 (80)/2 (10)
Eubacterium nodatum				
PDT	11 (55)/0 (0)	9 (45)/0 (0)	12 (60)/0 (0)	12 (63)/0 (0)
LDD	11 (55)/3 (15)	8 (40)/0 (0)	9 (45)/0 (0)*	9 (45)/0 (0)
Eikenella corrodens				
PDT	9 (45)/4 (20)	5 (25)/1 (5)	6 (30)/1 (5)	6 (32)/2 (11)
LDD	13 (65)/7 (35)	5 (25)/1 (5)**	2 (25)/0 (0)**	8 (40)/1 (5)**

*$P < 0.05$; **$P < 0.01$ compared with baseline (Wilcoxon test).
‡‡$P < 0.01$ between PDT and LDD group (Mann–Whitney test).

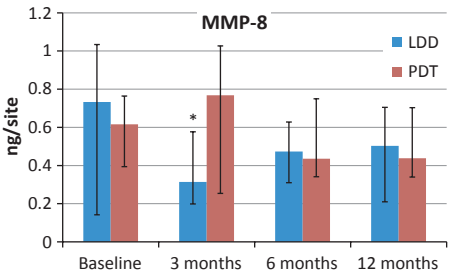

Fig. 1. Mean levels ± SD of matrix-metalloproteinase-8 (MMP-8) at baseline and after 3, 6 and 12 months in the PDT and LDD group, respectively. *$P < 0.05$ compared with baseline.

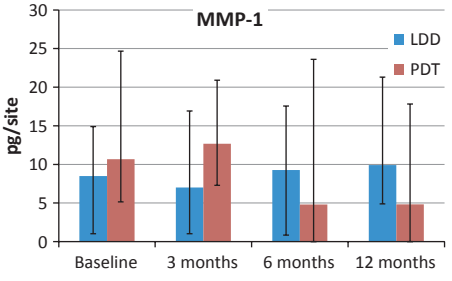

Fig. 2. Mean levels ± SD of matrix-metalloproteinase-1 (MMP-1) at baseline and after 3, 6 and 12 months in the PDT and LDD group, respectively.

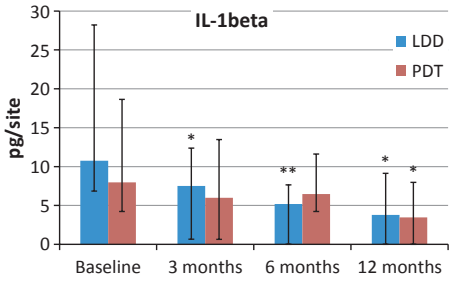

Fig. 3. Mean levels ± SD of IL-1β in the CF at baseline and after 3, 6 and 12 months in the PDT and LDD group, respectively. *$P < 0.05$; **$P < 0.01$ compared with baseline.

IL-10 were statistically significantly reduced in both groups after 3, 6 and 12 months.

Discussion

The aim of the present randomized controlled trial was to compare the clinical, microbiological and host-derived changes after non-surgical mechanical debridement of initial peri-implantitis lesions with either adjunctive photodynamic therapy or adjunctive local drug delivery. Treatment was delivered at baseline and was repeated at BoP+ sites after 3, 6, 9 and 12 months. After retreatment at 3 months, the number of BoP+ sites remained stable in both groups up to 12 months.

Despite the fact that a significantly higher percentage of patients treated with adjunctive PDT had a history of treated periodontitis when compared with that of the adjunctive antibiotic group, no significant differences were observed between groups with respect to clinical, microbiological and host-derived parameters after 12 months. Moreover, a decrease in the counts of red complex bacterial species (e.g. *P. gingivalis* and *T. forsythia*) and of IL-1β, IL-8, IL-10 and MMP-8 levels in the CF was observed in both groups.

Owing to the fact that non-surgical mechanical therapy alone of peri-implantitis was shown to have a minimal impact on changes in mucosal inflammation, pocket probing depth and microbiological parameters (Karring et al. 2005; Renvert et al. 2009), adjunctive delivery of minocycline microspheres (i.e. Arestin®) was selected as control therapy in the present study. Several studies investigated the benefits of adjunctive delivery of minocycline microspheres to the mechanical debridement of peri-implantitis lesions (Persson et al. 2006; Renvert et al. 2006, 2008; Salvi et al. 2007). The clinical effects of adjunctive delivery of minocycline microspheres (i.e. Arestin®) to non-

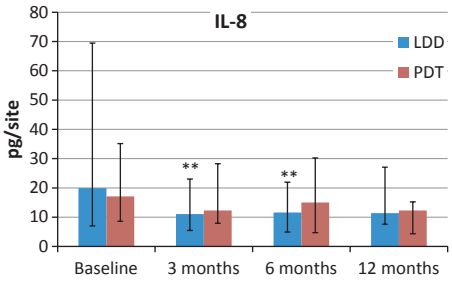

Fig. 4. Mean levels ± SD of IL-8 in the CF at baseline and after 3, 6 and 12 months in the PDT and LDD group, respectively. **$P < 0.01$ compared with baseline.

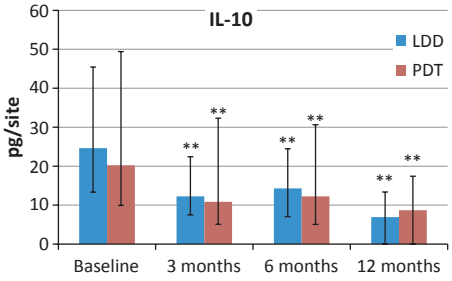

Fig. 5. Mean levels ± SD of IL-10 in the CF at baseline and after 3, 6 and 12 months in the PDT and LDD group, respectively. **$P < 0.01$ compared with baseline.

© 2013 John Wiley & Sons A/S. Published by Blackwell Publishing Ltd

surgical mechanical therapy were investigated in a case series of peri-implantitis lesions (Salvi et al. 2007). The results of that study showed significant reductions in mucosal inflammation and pocket probing depths up to 12 months (Salvi et al. 2007). Moreover, in that patient cohort treated with Arestin® (Salvi et al. 2007), reductions in levels of *T. forsythia*, *P. gingivalis* and *T. denticola* were reported up to 6 months (Persson et al. 2006). After the 6-month follow-up, however, bacterial recolonization of treated peri-implantitis sites was observed up to 12 months (Persson et al. 2006).

Larsen & Fiehn (1997) investigated developments of resistance of periodontal pathogens after exposure to minocycline *in vitro*. The outcomes of that study indicated that very high initial concentrations of minocycline were rapidly replaced by subinhibitory concentrations increasing the risk of development of bacterial resistance when repeated applications were performed (Larsen & Fiehn 1997). Conversely, the development of bacterial resistance to PDT was reported to be highly unlikely, even in the event of repeated applications (Raghavendra et al. 2009; Takasaki et al. 2009). Although PDT application was more time consuming compared with LDD delivery, repeated treatment of peri-implantitis lesions with PDT may yield a potential advantage from a microbiological point of view when compared with that of repeated minocycline applications.

Optimal conditions in terms of full-mouth plaque and bleeding scores (i.e. $\leq 25\%$) were instituted in the patients enroled in the present study before peri-implantitis therapy was delivered. Furthermore, excellent levels of self-performed plaque control were recorded during the 12-month study period contributing to the reduction in mucosal inflammation. Thus, minimal bacterial reservoirs were present in the residual dentition at baseline and after delivery of anti-infective therapy. Outcomes from clinical studies in periodontally compromized patients indicated that microbial transmission from residual periodontal pockets to implant surfaces represented a common phenomenon (Mombelli et al. 1995, Quirynen et al. 1996, 2006; Sumida et al. 2002; De Boever & De Boever 2006; Fürst et al. 2007; Salvi et al. 2008).

Long-term results from comparative studies revealed that patients with a history of treated periodontitis and rehabilitated with dental implants were more prone to develop biological complications compared with non-periodontitis patients (Hardt et al. 2002; Karoussis et al. 2003; De Boever et al. 2009; Matarasso et al. 2010; Roccuzzo et al. 2010, 2012). Therefore, the importance of supportive periodontal therapy in maintaining high survival and succes rates of implants placed in patients susceptible to periodontitis must be emphasized. This is reflected in the fact that patients with a history of treated periodontitis not compliant with regular supportive therapy displayed a higher incidence of implant losses and peri-implant bone loss ≥ 3 mm compared with compliant patients after an observation period of 10 years (Roccuzzo et al. 2010, 2012). Moreover, recent data indicated that periodontitis patients who received dental implants displayed a higher rate of compliance with scheduled supportive therapy appointments compared with patients not experiencing implant therapy (Cardaropoli & Gaveglio 2012).

The first therapeutic step for all implants in the present study included mechanical debridement with titanium currettes followed by a glycine-based powder airpolishing and irrigation with 3% hydrogen peroxide. Sahm et al. (2011) reported a significant reduction in bleeding scores when the rough implant surface was debrided with a glycine-based air-abrasive device compared with mechanical debridement with carbon fibre curettes and local delivery of chlorhexidine. Irrigation of the peri-implant pockets with 3% hydrogen peroxide in the present study was based on the effects of this chemical agent against bacterial lipopolysaccharides attached to the implant surface (Zablotsky et al. 1992).

The clinical outcomes of the present study support the fact that reduction in the number of sites bleeding on probing occurred predominantly during the first 3 months after therapy in both groups. Complete resolution of mucosal inflammation, however, was achieved in 31.6% of implants receiving adjunctive PDT and in 35% of implants with adjunctive local drug delivery after 12 months. Therefore, 68.4% of the implants in the PDT group and 65% of the implants in the LDD group were retreated after 12 months. This is in agreement with previous reports on non-surgical anti-infective treatment protocols that failed to yield complete resolution of mucosal inflammation after observation periods ranging from 6 to 12 months (Mombelli & Lang 1992; Karring et al. 2005; Salvi et al. 2007; Renvert et al. 2008, 2009; Sahm et al. 2011). Parallel to the reduction in mucosal inflammation, significant reductions in PPD ranging from 0.27 to 0.46 mm were observed during the first 3 months after therapy in both groups. No further significant reductions in PPD occurred between 3 and 12 months. The reduction in PPD from baseline to 3 months was accompanied by a significant reduction in the counts of red complex bacteria (i.e. *P. gingivalis*, *T. denticola* and *T. forsythia*) in both groups. Moreover, crevicular fluid levels of IL-1β, IL-8, IL-10 and MMP-8 decreased from baseline to 12 months in both groups. The diagnostic potential of CF levels of IL-1β, IL-8, IL-10 and MMP-8 in discriminating healthy from inflamed peri-implant sites was suggested in various studies (Salcetti et al. 1997; Teronen et al. 1997; Kivelä-Rajamäki et al. 2003a,b; Xu et al. 2008; Duarte et al. 2009; Petkovic et al. 2010). Reductions in CF levels of IL-1β were reported after non-surgical therapy of chronic periodontitis with the adjunctive delivery of minocycline microspheres (Oringer et al. 2002) and the adjunctive application of PDT (Lui et al. 2011). Crevicular fluid levels of IL-1β increased significantly after 3 weeks of experimental plaque accumulation around dental implants and were reversed to pre-experimental levels after reestablishment of self-performed oral hygiene practices (Schierano et al. 2008; Salvi et al. 2012).

After non-surgical therapy of peri-implantitis with adjunctive local delivery of minocycline microspheres, a mean reduction in PPD of 1 mm was reported after 3 months around implants with mean baseline PPD (e.g. 4.5 mm) comparable with those in the present study (Salvi et al. 2007). However, at sites with mean baseline PPD of 3.85 and 3.87 mm, reductions in PPD of 0.17 mm and 0.19 mm were reported 3 months after therapy of peri-implantitis with local delivery of minocycline microspheres or application of chlorhexidine gel, respectively (Renvert et al. 2008). It should be noted, however, that in that study no mechanical debridement preceded the application of the adjunctive drug deliveries (Renvert et al. 2008). Outcomes of a clinical trial showed that greater reductions in pocket probing depths (e.g. 0.8 mm) compared with those in the present study were achieved 3 months after non-surgical therapy of peri-implantitis by means of an air-abrasive device or mechanical debridement and local chlorhexidine application (Sahm et al. 2011). These reported differences among clinical study outcomes may be partly explained by different PPD at baseline and/or the invasiveness of the treatment protocols.

In conclusion, the outcomes of this randomized clinical trial demonstrated that mechanical disruption of the submucosal biofilm with the adjunctive delivery of PDT or LDD in conjunction with optimal self-perfomed plaque control yielded improvements in clinical, microbiological and host-derived parameters. Both treatment modalities yielded comparable reductions in mucosal inflammation and pocket probing depths up to 12 months. Complete resolution of mucosal inflammation, however, was not routinely achieved with either of the adjunctive therapies.

© 2013 John Wiley & Sons A/S. Published by Blackwell Publishing Ltd

Acknowledgement: The authors gratefully acknowledge the statistical expertise of Mr. Walter B. Bürgin, Biomed. Ing., University of Bern, School of Dental Medicine.

Source of funding statement

The study was funded by Bredent Medical GmbH & Co. KG, Geschäftsbereich HELBO, Walldorf, Germany.

Conflict of interest

The authors do not report any conflicts of interest.

References

Aglietta, M., Iorio Siciliano, V., Rasperini, G., Cafiero, C., Lang, N.P. & Salvi, G.E. (2011) A 10-year retrospective analysis of marginal bone-level changes around implants in periodontally healthy and periodontally compromised tobacco smokers. *Clinical Oral Implants Research* **22**: 47–53.

Büchter, A., Meyer, U., Kruse-Losler, B., Joos, U. & Kleinheinz, J. (2004) Sustained release of doxycycline for the treatment of peri-implantitis: Randomised controlled trial. *British Journal of Oral and Maxillofacial Surgery* **42**: 439–444.

Buser, D., Janner, S.F., Wittneben, J.G., Brägger, U., Ramseier, C.A. & Salvi, G.E. (2012) 10-year survival and success rates of 511 titanium implants with a sandblasted and acid-etched surface: A retrospective study in 303 partially edentulous patients. *Clinical Implant Dentistry and Related Research* **14**: 839–851.

Cardaropoli, D. & Gaveglio, L. (2012) Supportive periodontal therapy and dental implants: An analysis of patients' compliance. *Clinical Oral Implants Research* **23**: 1385–1388.

De Boever, A.L. & De Boever, J.A. (2006) Early colonization of non-submerged dental implants in patients with a history of advanced aggressive periodontitis. *Clinical Oral Implants Research* **17**: 8–17.

De Boever, A.L., Quirynen, M., Coucke, W., Theuniers, G. & De Boever, J.A. (2009) Clinical and radiographic study of implant treatment outcome in periodontally susceptible and non-susceptible patients: A prospective long-term study. *Clinical Oral Implants Research* **20**: 1341–1350.

Dierens, M., Vandeweghe, S., Kisch, J., Nilner, K. & De Bruyn, H. (2012) Long-term follow-up of turned single implants placed in periodontally healthy patients after 16–22 years: Radiographic and peri-implant outcome. *Clinical Oral Implants Research* **23**: 197–204.

Duarte, P.M., de Mendonca, A.C., Maximo, M.B., Santos, V.R., Bastos, M.F. & Nociti Junior, F.H. (2009) Differential cytokine expressions affect the severity of peri-implant disease. *Clinical Oral Implants Research* **20**: 514–520.

Eick, S., Straube, A., Guentsch, A., Pfister, W. & Jentsch, H. (2011) Comparison of real-time polymerase chain reaction and DNA-strip technology in microbiological evaluation of periodontitis treatment. *Diagnostic Microbiology and Infectious Disease* **69**: 12–20.

Frisch, E., Ziebolz, D. & Rinke, S. (2012) Long-term results of implant-supported over-dentures retained by double crowns: A practice-based retrospective study after minimally 10 years follow-up. *Clinical Oral Implants Research*. doi: 10.1111/j.1600-0501.2012.02568.x.

Fürst, M.M., Salvi, G.E., Lang, N.P. & Persson, G.R. (2007) Bacterial colonization immediately after installation on oral titanium implants. *Clinical Oral Implants Research* **18**: 501–508.

Hardt, C.R., Gröndahl, K., Lekholm, U. & Wennström, J.L. (2002) Outcome of implant therapy in relation to experienced loss of periodontal bone support: A retrospective 5- year study. *Clinical Oral Implants Research* **13**: 488–494.

Hayek, R.R., Araujo, N.S., Gioso, M.A., Ferreira, J., Baptista-Sobrinho, C.A., Yamada, A.M. & Ribeiro, M.S. (2005) Comparative study between the effects of photodynamic therapy and conventional therapy on microbial reduction in ligature-induced peri-implantitis in dogs. *Journal of Periodontology* **76**: 1275–1281.

Hultin, M., Gustafsson, A., Hallström, H., Johansson, L.A., Ekfeldt, A. & Klinge, B. (2002) Microbiological findings and host response in patients with peri-implantitis. *Clinical Oral Implants Research* **13**: 349–358.

Karoussis, I.K., Salvi, G.E., Heitz-Mayfield, L.J., Brägger, U., Hammerle, C.H. & Lang, N.P. (2003) Long-term implant prognosis in patients with and without a history of chronic periodontitis: A 10-year prospective cohort study of the iti dental implant system. *Clinical Oral Implants Research* **14**: 329–339.

Karring, E.S., Stavropoulos, A., Ellegaard, B. & Karring, T. (2005) Treatment of peri-implantitis by the vector system. *Clinical Oral Implants Research* **16**: 288–293.

Kivelä-Rajamäki, M., Maisi, P., Srinivas, R., Tervahartiala, T., Teronen, O., Husa, V., Salo, T. & Sorsa, T. (2003a) Levels and molecular forms of mmp-7 (matrilysin-1) and mmp-8 (collagenase-2) in diseased human peri-implant sulcular fluid. *Journal of Periodontal Research* **38**: 583–590.

Kivelä-Rajamäki, M.J., Teronen, O.P., Maisi, P., Husa, V., Tervahartiala, T.I., Pirila, E.M., Salo, T.A., Mellanen, L. & Sorsa, T.A. (2003b) Laminin-5 gamma2-chain and collagenase-2 (mmp-8) in human peri-implant sulcular fluid. *Clinical Oral Implants Research* **14**: 158–165.

Lang, N.P., Joss, A., Orsanic, T., Gusberti, F.A. & Siegrist, B.E. (1986) Bleeding on probing. A predictor for the progression of periodontal disease? *Journal of Clinical Periodontology* **13**: 590–596.

Larsen, T. & Fiehn, N.E. (1997) Development of resistance to metronidazole and minocycline in vitro. *Journal of Clinical Periodontology* **24**: 254–259.

Leonhardt, A., Renvert, S. & Dahlen, G. (1999) Microbial findings at failing implants. *Clinical Oral Implants Research* **10**: 339–345.

Lui, J., Corbet, E.F. & Jin, L. (2011) Combined photodynamic and low-level laser therapies as an adjunct to nonsurgical treatment of chronic periodontitis. *Journal of Periodontal Research* **46**: 89–96.

Marotti, J., Tortamano, P., Cai, S., Ribeiro, M.S., Franco, J.E. & de Campos, T.T. (2013) Decontamination of dental implant surfaces by means of photodynamic therapy. *Lasers in Medical Science* **28**: 303–309.

Matarasso, S., Rasperini, G., Iorio Siciliano, V., Salvi, G.E., Lang, N.P. & Aglietta, M. (2010) A 10-year retrospective analysis of radiographic bone-level changes of implants supporting single-unit crowns in periodontally compromised vs. Periodontally healthy patients. *Clinical Oral Implants Research* **21**: 898–903.

Mombelli, A., Feloutzis, A., Brägger, U. & Lang, N.P. (2001) Treatment of peri-implantitis by local delivery of tetracycline. Clinical, microbiological and radiological results. *Clinical Oral Implants Research* **12**: 287–294.

Mombelli, A. & Lang, N.P. (1992) Antimicrobial treatment of peri-implant infections. *Clinical Oral Implants Research* **3**: 162–168.

Mombelli, A., Marxer, M., Gaberthüel, T., Grunder, U. & Lang, N.P. (1995) The microbiota of osseointegrated implants in patients with a history of periodontal disease. *Journal of Clinical Periodontology* **22**: 124–130.

Mombelli, A., van Oosten, M.A., Schürch, E., Jr & Lang, N.P. (1987) The microbiota associated with successful or failing osseointegrated titanium implants. *Oral Microbiology and Immunology* **2**: 145–151.

Oringer, R.J., Al-Shammari, K.F., Aldridge, W.A., Iacono, V.J., Eber, R.M., Wang, H.L., Berwald, B., Nejat, R. & Giannobile, W.V. (2002) Effect of locally delivered minocycline microspheres on markers of bone resorption. *Journal of Periodontology* **73**: 835–842.

Persson, G.R., Salvi, G.E., Heitz-Mayfield, L.J. & Lang, N.P. (2006) Antimicrobial therapy using a local drug delivery system (arestin) in the treatment of peri-implantitis. I: Microbiological outcomes. *Clinical Oral Implants Research* **17**: 386–393.

Petkovic, A.B., Matic, S.M., Stamatovic, N.V., Vojvodic, D.V., Todorovic, T.M., Lazic, Z.R. & Kozomara, R.J. (2010) Proinflammatory cytokines (il-1beta and tnf-alpha) and chemokines (il-8 and mip-1alpha) as markers of peri-implant tissue condition. *International Journal of Oral and Maxillofacial Surgery* **39**: 478–485.

Quirynen, M., Papaioannou, W. & van Steenberghe, D. (1996) Intraoral transmission and the colonization of oral hard surfaces. *Journal of Periodontology* **67**: 986–993.

Quirynen, M., Vogels, R., Peeters, W., van Steenberghe, D., Naert, I. & Haffajee, A.D. (2006) Dynamics of initial subgingival colonization of 'pristine' peri-implant pockets. *Clinical Oral Implants Research* **17**: 25–37.

Raghavendra, M., Koregol, A. & Bhola, S. (2009) Photodynamic therapy: A targeted therapy in periodontics. *Australian Dental Journal* **54**(Suppl. 1): 102–109.

© 2013 John Wiley & Sons A/S. Published by Blackwell Publishing Ltd

Renvert, S., Lessem, J., Dahlen, G., Lindahl, C. & Svensson, M. (2006) Topical minocycline microspheres versus topical chlorhexidine gel as an adjunct to mechanical debridement of incipient peri-implant infections: A randomized clinical trial. *Journal of Clinical Periodontology* **33**: 362–369.

Renvert, S., Lessem, J., Dahlen, G., Renvert, H. & Lindahl, C. (2008) Mechanical and repeated antimicrobial therapy using a local drug delivery system in the treatment of peri-implantitis: A randomized clinical trial. *Journal of Periodontology* **79**: 836–844.

Renvert, S., Lessem, J., Lindahl, C. & Svensson, M. (2004) Treatment of incipient peri-implant infections using topical minocycline microspheres versus topical chlorhexidine gel as an adjunct to mechanical debridement. *Journal of the International Academy of Periodontology* **6**: 154–159.

Renvert, S., Samuelsson, E., Lindahl, C. & Persson, G.R. (2009) Mechanical non-surgical treatment of peri-implantitis: A double-blind randomized longitudinal clinical study. I: Clinical results. *Journal of Clinical Periodontology* **36**: 604–609.

Roccuzzo, M., Bonino, F., Aglietta, M. & Dalmasso, P. (2012) Ten-year results of a three arms prospective cohort study on implants in periodontally compromised patients. Part 2: Clinical results. *Clinical Oral Implants Research* **23**: 389–395.

Roccuzzo, M., De Angelis, N., Bonino, L. & Aglietta, M. (2010) Ten-year results of a three-arm prospective cohort study on implants in periodontally compromised patients. Part 1: Implant loss and radiographic bone loss. *Clinical Oral Implants Research* **21**: 490–496.

Sahm, N., Becker, J., Santel, T. & Schwarz, F. (2011) Non-surgical treatment of peri-implantitis using an air-abrasive device or mechanical debridement and local application of chlorhexidine: A prospective, randomized, controlled clinical study. *Journal of Clinical Periodontology* **38**: 872–878.

Salcetti, J.M., Moriarty, J.D., Cooper, L.F., Smith, F.W., Collins, J.G., Socransky, S.S. & Offenbacher, S. (1997) The clinical, microbial, and host response characteristics of the failing implant. *International Journal of Oral and Maxillofacial Implants* **12**: 32–42.

Salmeron, S., Rezende, M.L., Consolaro, A., Sant'ana, A.C., Damante, C.A., Greghi, S.L. & Passanezi, E. (2012) Laser therapy as an effective method for implant surface decontamination: A histomorphometric study in rats. *Journal of Periodontology*. doi:10.1902/jop.2012.120166.

Salvi, G.E., Aglietta, M., Eick, S., Sculean, A., Lang, N.P. & Ramseier, C.A. (2012) Reversibility of experimental peri-implant mucositis compared with experimental gingivitis in humans. *Clinical Oral Implants Research* **23**: 182–190.

Salvi, G.E., Fürst, M.M., Lang, N.P. & Persson, G.R. (2008) One-year bacterial colonization patterns of staphylococcus aureus and other bacteria at implants and adjacent teeth. *Clinical Oral Implants Research* **19**: 242–248.

Salvi, G.E., Persson, G.R., Heitz-Mayfield, L.J., Frei, M. & Lang, N.P. (2007) Adjunctive local antibiotic therapy in the treatment of peri-implantitis ii: Clinical and radiographic outcomes. *Clinical Oral Implants Research* **18**: 281–285.

Schär, D., Ramseier, C.A., Eick, S., Arweiler, N.B., Sculean, A. & Salvi, G.E. (2013) Anti-infective therapy of peri-implantitis with adjunctive local drug delivery or photodynamic therapy: Six-month outcomes of a prospective randomized clinical trial. *Clinical Oral Implants Research* **24**: 104–110.

Schierano, G., Pejrone, G., Brusco, P., Trombetta, A., Martinasso, G., Preti, G. & Canuto, R.A. (2008) Tnf-alpha tgf-beta2 and il-1beta levels in gingival and peri-implant crevicular fluid before and after de novo plaque accumulation. *Journal of Clinical Periodontology* **35**: 532–538.

Schwarz, F., Sculean, A., Rothamel, D., Schwenzer, K., Georg, T. & Becker, J. (2005) Clinical evaluation of an er:Yag laser for nonsurgical treatment of peri-implantitis: A pilot study. *Clinical Oral Implants Research* **16**: 44–52.

Serino, G. & Ström, C. (2009) Peri-implantitis in partially edentulous patients: Association with inadequate plaque control. *Clinical Oral Implants Research* **20**: 169–174.

Shibli, J.A., Martins, M.C., Theodoro, L.H., Lotufo, R.F., Garcia, V.G. & Marcantonio, E.J. (2003) Lethal photosensitization in microbiological treatment of ligature-induced peri-implantitis: A preliminary study in dogs. *Journal of Oral Sciences* **45**: 17–23.

Socransky, S.S., Haffajee, A.D., Cugini, M.A., Smith, C. & Kent, R.L. Jr (1998) Microbial complexes in subgingival plaque. *Journal of Clinical Periodontology* **25**: 134–144.

Subramani, K., Jung, R.E., Molenberg, A. & Hämmerle, C.H. (2009) Biofilm on dental implants: A review of the literature. *International Journal of Oral and Maxillofacial Implants* **24**: 616–626.

Sumida, S., Ishihara, K., Kishi, M. & Okuda, K. (2002) Transmission of periodontal disease-associated bacteria from teeth to osseointegrated implant regions. *International Journal of Oral and Maxillofacial Implants* **17**: 696–702.

Takasaki, A.A., Aoki, A., Mizutani, K., Schwarz, F., Sculean, A., Wang, C.Y., Koshy, G., Romanos, G., Ishikawa, I. & Izumi, Y. (2009) Application of antimicrobial photodynamic therapy in periodontal and peri-implant diseases. *Periodontology 2000* **51**: 109–140.

Teronen, O., Konttinen, Y.T., Lindqvist, C., Salo, T., Ingman, T., Lauhio, A., Ding, Y., Santavirta, S. & Sorsa, T. (1997) Human neutrophil collagenase mmp-8 in peri-implant sulcus fluid and its inhibition by clodronate. *Journal of Dental Research* **76**: 1529–1537.

Ueda, T., Kremer, U., Katsoulis, J. & Mericske-Stern, R. (2011) Long-term results of mandibular implants supporting an overdenture: Implant survival, failures, and crestal bone level changes. *International Journal of Oral and Maxillofacial Implants* **26**: 365–372.

Xu, L., Yu, Z., Lee, H.M., Wolff, M.S., Golub, L.M., Sorsa, T. & Kuula, H. (2008) Characteristics of collagenase-2 from gingival crevicular fluid and peri-implant sulcular fluid in periodontitis and peri-implantitis patients: Pilot study. *Acta Odontologica Scandinavica* **66**: 219–224.

Yang, J.L., Wang, M.S., Cheng, A.C., Pan, K.C., Li, C.F. & Deng, S.X. (2008) A simple and rapid method for extracting bacterial DNA from intestinal microflora for ERIC-PCR detection. *World Journal of Gastroenterology* **14**: 2872–2876.

Zablotsky, M.H., Diedrich, D.L. & Meffert, R.M. (1992) Detoxification of endotoxin-contaminated titanium and hydroxyapatite-coated surfaces utilizing various chemotherapeutic and mechanical modalities. *Implant Dentistry* **1**: 154–158.

Supporting Information

Additional Supporting Information may be found in the online version of this article:

Data S1. CONSORT 2010 checklist of information to include when reporting a randomised trial.

© 2013 John Wiley & Sons A/S. Published by Blackwell Publishing Ltd